

## RESEARCH ARTICLE

# Evaluation of endothelial function after using high concentration and prolonged exposure of mitomycin C following photorefractive keratectomy for high myopia and astigmatism

Tamer Adel Refai, MD<sup>1</sup>, Olfat A. Hassanin, MD<sup>1</sup>

### ABSTRACT

**Purpose:** To evaluate endothelial function after using high concentration and prolonged exposure of mitomycin C following PRK for high myopia and astigmatism.

**Participants:** Twenty-two eyes of highly myopic patients with or without astigmatism seeking refractive correction.

**Methods:** Twenty-two (22) eyes of fourteen(14) patients with high myopia (more than 6 diopters myopia together with astigmatism) seeking for refractive correction at the research institute of ophthalmology-Egypt, were subjected to Photorefractive keratectomy (PRK) using the ALLEGRETTO WAVE EYE-Q 1010 with application of high concentration of mitomycin C 0.027% for more than two minutes after excimer laser ablation. Postoperatively, patients were given topical moxifloxacin eye drops, steroid eye drops, NSAIDs eye drops in addition to oral analgesics. A contact lens was applied to counteract pain and is removed once the epithelium was healed. Patients will be examined 1,6,7 days, 2 weeks and 1,2 months after surgery. Specular microscopy was performed before surgery and again 1-2 months after PRK to detect any possible reduction of endothelial function. Final corneal haze as well as BCVA were reported at 1-2 months after stabilization of refractive error. Collected data were subjected to statistical analysis including determination of mean value, standard deviation of each studied item in addition to minimum and maximum values. Comparison tests (t-test) as well as correlation tests were performed.

**Results:** The age ranged from 18-39 years (mean 28.10±6.24).The corrected sphere (D) ranged from -3.0 to -10.0 (mean -6.82±2.08), cylinder (D) ranged from -1.0 to -4.5 (mean -2.56±1.13) and the total spherocylindrical correction (D) ranged from -6.25 to -11.25 (mean -8.78±1.52). No significant corneal haze developed in any of the cases included in the study. Regarding specular microscopy, the endothelial cell density(CD)/ mm<sup>2</sup> changed from a mean value of 2667.05±218.35 preoperatively to a mean value of 2697.32± 245.97 at 1-2 months postoperatively with a non-significant difference (p>0.05). The average endothelial cell area (Avg) (µm<sup>2</sup>) changed from a mean value

### Correspondence to:

Dr. Tamer AR

<sup>1</sup>Refractive Unit, Ophthalmology Department, Research Institute of Ophthalmology

Email: [tamerrefai@hotmail.com](mailto:tamerrefai@hotmail.com)

©JORS

<http://jors.journals.ekb.eg/>

Full list of author information is available at the end of the article.

of  $377.41 \pm 31.38$  preoperatively to a mean value of  $373.77 \pm 36.51$  at 1-2 months postoperatively with a non-significant difference ( $p > 0.05$ ). The average coefficient of variation in cell size (CV) i.e; polymegathism changed from a mean value of  $28.22 \pm 6.98$  preoperatively to a mean value of  $26.09 \pm 4.39$  at 1-2 months postoperatively with a non-significant difference ( $p > 0.05$ ). The average hexagonal cells percentage (Hex%) i.e; pleomorphism, changed from a mean value of  $68.18 \pm 8.35$  preoperatively to a mean value of  $69.95 \pm 6.47$  at 1-2 months postoperatively with a non-significant difference ( $p > 0.05$ ). A non-significant correlation ( $P > 0.05$ ) existed between length of mitomycin C exposure and post-PRK changes in the cell density (CD) ( $r = 0.14$ ), average cell area change ( $r = -0.18$ ) as well as coefficient of variation in cell size (CV) ( $r = 0.02$ ) but there was a statistically significant correlation between the length of mitomycin C exposure and post-PRK changes in the hexagonal cells percentage ( $p < 0.05$ ,  $r = 0.37$ ).

**Conclusion:** Photorefractive keratectomy using higher concentration of mitomycin C (0.027%) for exposure time of (2.20-3 minutes) provided excellent refractive and visual results for high myopia and astigmatism without significant negative effects on the corneal endothelium.

**Keywords:** High myopia with astigmatism-high concentration of mitomycin C with prolonged exposure-Endothelial cell changes.

## Introduction

Laser in situ keratomileusis (LASIK) is commonly used to treat wide range of refractive errors with excellent results and relatively low complication rates<sup>1</sup>. However, creation of the lamellar cut in the anterior stroma in addition to corneal stromal tissue loss can cause weakening of the biomechanical properties of the cornea resulting in progressive ectasia particularly in correction of high errors<sup>2</sup>. There are also case in which the preoperative corneal thickness is very thin relative to the refractive error that needs correction, resulting either in insufficient residual stromal bed that may predispose to ectasia, or limiting the surgeon to use smaller ablation zones, resulting in disturbances in night vision and haloes and glare when pupil dilates in dim illumination<sup>3</sup>. The use of surface ablation, like photorefractive keratectomy can provide less stress on the corneal biomechanical properties (by avoiding the lamellar cut creation); thus allowing correction of higher refractive errors while preserving more additional residual stromal bed, but unfortunately it can result in significant postoperative corneal haze limiting post-ablative visual quality<sup>4</sup>. Mitomycin C is an alkylating agent for DNA which is derived from *Streptomyces caespitosus*. It was proven that it decreased corneal haze after excimer laser ablation both in animal<sup>5</sup> and human studies<sup>6</sup> by inhibiting DNA/RNA replication in fibroblasts<sup>7</sup>. The Incidence of corneal haze was found to be higher as the depth of ablation is increased as in treating patients with high myopia (i.e above 6 diopters of myopia) compared to patients with lesser degrees of myopia<sup>9</sup>. Several concentrations of the mitomycin C were tried in which a standard concentration of (0.02%) proved to be more effective than a lower concentration

of (0.002%) in avoiding post-surface ablation haze without inducing serious complications<sup>9-10</sup>. The duration of mitomycin C application can be related to increased toxicity<sup>11</sup>. Several durations of exposure had been used ranging from 15 seconds to 2 minutes, with longer applications applies for higher refractive corrections<sup>12-14</sup>. Some studies showed significant endothelial cell changes after PRK with mitomycin<sup>15-16</sup>, while others showed no significant changes<sup>17</sup>. In our practice in photorefractive keratectomy which we routinely used mitomycin C (0.02%) application for 2 minutes, we met cases with grade 1 corneal haze with few cases with moderate to high refractive errors which may sometimes decrease visual quality, so after discussing the refractive options with patients with higher errors, we evaluated the use of a slightly higher (0.027%) than standard concentration (0.02%) of mitomycin C for high myopic corrections with astigmatism aiming achieve better visual and refractive results while validating its safety on the corneal endothelial cells.

## Purpose

To evaluate endothelial function after using high concentration and prolonged exposure of mitomycin C following photorefractive keratectomy for high myopia.

## Methods

Twenty-two (22) eyes of fourteen (14) highly myopic patient (more than 6 diopters myopia together with astigmatism) seeking refractive surgery at the research institute of ophthalmology between July 2018 and August 2019 were subjected to Photorefractive keratectomy (PRK) using the ALLEGRETTO WAVE EYE-Q 1010 with application of high concentration of

## Correspondence to:

Dr. Tamer AR

<sup>1</sup>Refractive Unit, Ophthalmology Department, Research Institute of Ophthalmology

©JORS

Email: [tamerrefai@hotmail.com](mailto:tamerrefai@hotmail.com)

<http://jors.journals.ekb.eg/>

Full list of author information is available at the end of the article.

mitomycin C 0.027% for 2.2-3minutes after excimer laser ablation. After excluding other refractive options; like laser in situ keratomileusis, phakic IOLs ,or refractive lens exchange for a variety of reasons whether medical, psychological or economical, patients were informed about the technique and its possible risks and a written consent is taken. Exclusion criteria included: suspected or diagnosed keratoconus patients, patients below 18 years old, eyes with previous ocular surgery or trauma, eyes with corneal endothelial count below 2000 cells/mm<sup>2</sup>, eyes with blue (thin sclera), pregnant or lactating ladies, eyes with central corneal thickness below 500µ, eyes with dry eye symptoms, recurrent erosion syndrome, systemic diseases or medications that impair epithelial healing, eyes with abnormal corneal biomechanics by ocular response analyzer (ORA) as well as yes with significant post-PRK haze that impair specular microscopy examination.

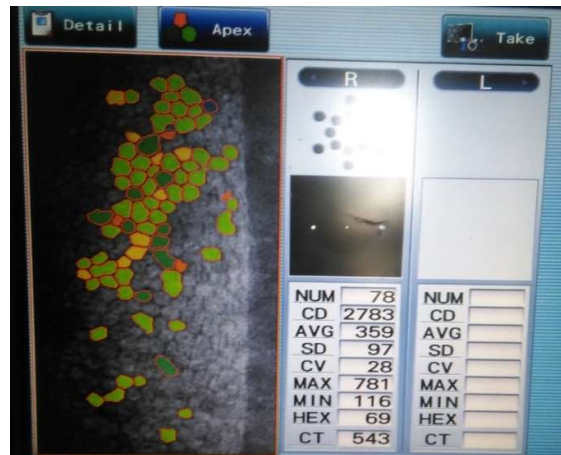**PRK with mitomycin C application technique:**

Topical anaesthesia (Proparacaine hydrochloride 0.4%) is applied twice, followed by mechanical debridement for the central 8mm diameter epithelium with a blunt end of spatula keeping the cornea *wet* all the time to enable smooth debridement. Excimer laser ablation by the ALLEGRETTO WAVE EYE-Q 1010 using a nomogram where 10% under-correction was used (to avoid overcorrection associated with mitomycin C usage). Mitomycin C 0.027% is applied for 2.20 minutes-3 minutes(according to the extent of refractive correction)(**table 1**) to the ablation site following laser ablation and then washed thoroughly with cold BSS with meticulous washing of the corneal bed, fornices, the lid margins and the puncti to remove any traces of mitomycin C to avoid endothelial toxicity and limbal stem cells toxicity followed by application of a drop of antibiotic-steroid combination and the applying a bandage contact lens for 4 days.

|                                      | Average refractive correction in diopters | Mitomycin C Exposure time in minutes |
|--------------------------------------|---|--------------------------------------|
| Corrected range (>-6 to -8) diopters | -7.13(D)                                  | 2.2                                  |
| Corrected range (>8 to<-12) diopters | -9.71(D)                                  | 2.5                                  |

**Table 1:** Average mitomycin C (0.027%) exposure time following PRK according to extent of refractive correction among study.

Postoperatively, patients were given topical moxifloxacin eye drops, steroid eye drops, NSAIDs eye drops in addition to oral analgesics. A contact lens was applied to counteract pain and is removed once the epithelium was healed. Patients will be examined 1,4,7 days,2 weeks and 1,2 months after surgery. During each visit. Slit lamp examination was done to detect possible haze (and treat accordingly),UCVA, BCVA, in addition to IOP(to exclude steroid induced glaucoma).Specular microscopy was performed with NIDEK SPECULAR MICROSCOPE CSM-530, before surgery and again 1-2 months after PRK to detect any possible reduction of endothelial function related to the higher concentration (0.027%) and prolonged concentration (more than 2 minutes ) of mitomycin than traditional application in refractive ablation (0.02%) with limited exposure time to 20 seconds. The main specular microscopic studied functions were; endothelial cell density (CD), average cell area (Avg), cell size coefficient of variation (CV) to determine quantitative assessment of polymegathism, percentage of hexagonal cells (Hex%) to determine variability in endothelial cell shape (pleomorphism) as well as corneal thickness(CT) (**figure1**).



**Figure 1:** Specular microscopy with the NIDEK SPECULAR MICROSCOPE CSM-530 before PRK-with motomycin C application of one of our cases under study.

Final corneal haze grade (**figure 2**) according to Joon Mo Kim Grading scale for corneal haze after photoablation<sup>18</sup>as well as BCVA were reported at 1-2 months after stabilization of refractive error.

**Correspondence to:**

Dr. Tamer AR

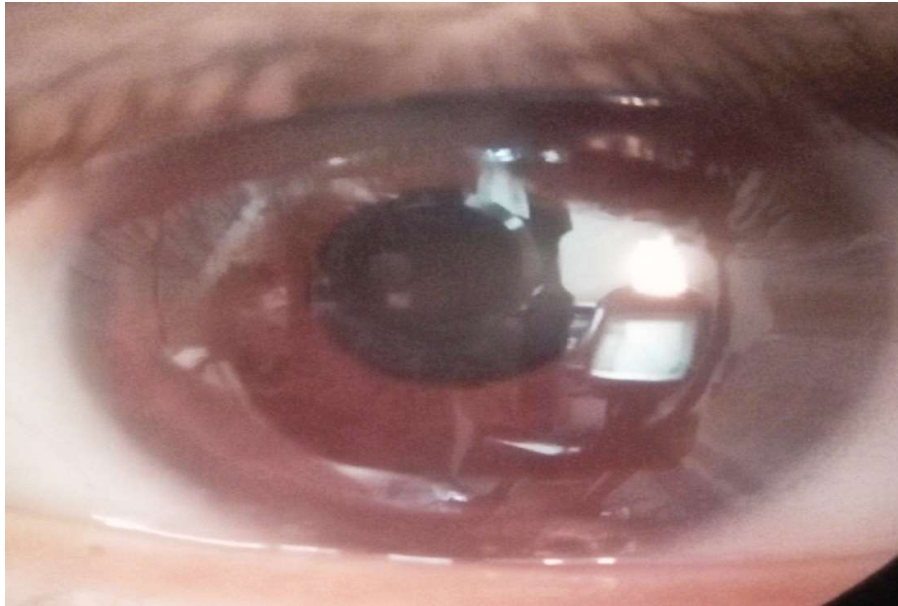
<sup>1</sup>Refractive Unit, Ophthalmology Department, Research Institute of Ophthalmology

Email:[tamerrefai@hotmail.com](mailto:tamerrefai@hotmail.com)

Full list of author information is available at the end of the article.

©JORS

<http://jors.journals.ekb.eg/>



**Figure 2:** Grade 0.5 corneal haze in a case with PRK with mitomycin C among study.

Collected data were subjected to statistical analysis including determination of mean value, standard deviation, minimum and maximum values. Comparison tests (t-test) as well as correlation tests were performed.

**Results**

Preoperatively, the age ranged from 18-39 years (mean 28.10±6.24). The average keratometric readings ranged from 41.2-44.75(D) (mean 43.12±1.02).The central pachymetry (μ) ranged from 510-571μ (mean 537.5±17.31). The sphere (D) ranged from -3.0 to -10.0 (mean -6.82±2.08). The cylinder (D) ranged from -1.0 to -4.5 (mean -2.56±1.13). The total spherocylindrical correction (D) ranged from -6.25 to -11.25 (mean -8.78±1.52). The best corrected visual acuity in Snellen lines ranged from 0.2 to 1.0 (mean 0.55±0.22). The corneal hysteresis (CH) ranged from 8.9 to 14.1 (mean 10.43±1.16). The corneal resistance factor (CRF) ranged from 9.1 to 12.3 (mean 10.35±0.95)(table 2).

The visual acuity in Snellen lines increased from a mean value of 0.55±0.22 for the preoperative best corrected visual acuity to a mean value of 0.61±0.17for the uncorrected visual acuity with t-test showing a non-significant difference(>0.05)(table 3 and chart 1).

No case with or exceeding grade 1 corneal haze according to Joon Mo Kim Grading scale for corneal haze after photoablation<sup>18</sup> developed in any cases included in the study.

**Correspondence to:**

Dr. Tamer AR

<sup>1</sup>Refractive Unit, Ophthalmology Department, Research Institute of Ophthalmology

Email:[tamerrefai@hotmail.com](mailto:tamerrefai@hotmail.com)

Full list of author information is available at the end of the article.

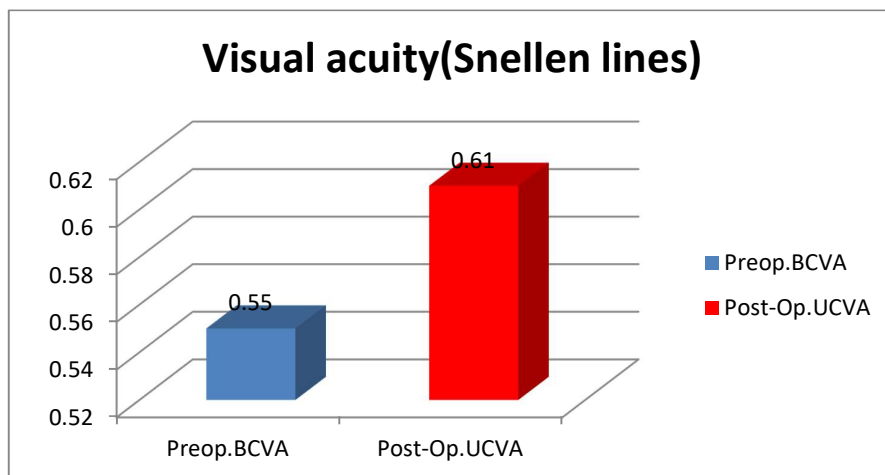
| Item   | Mean±SD     | Range           |
|--|-------------|-----------------|
| Age(years)                                       | 28.10±6.24  | 18-39           |
| Average keratometric readings(D)                 | 43.12±1.02  | 41.2-44.75      |
| Central pachymetry(μ)                            | 537.5±17.31 | 510-571         |
| Sphere(D)  | -6.82±2.08  | -3.0 to -10.0   |
| Cylinder(D)                                      | -2.56±1.13  | -1.0 to -4.5    |
| Total spherocylindrical correction(D)            | -8.78±1.52  | -6.25 to -11.25 |
| Best corrected visual acuity Snellen lines(BCVA) | 0.55±0.22   | 0.2 to 1.0      |
| Corneal hysteresis(CH)                           | 10.43±1.16  | 8.9 to 14.1     |
| Corneal resistance factor (CRF)                  | 10.35±0.95  | 9.1 to 12.3     |

**Table 2:** Demographic data

The corneal endothelial cell density (CD)/ mm<sup>2</sup> changed from a mean value of 2667.05±218.35 preoperatively to a mean value of 2697.32±245.97 at 1-2 months postoperatively with t-test value of 1.07 denoting a non-significant difference (p>0.05) (table 4 and chart 2).The average endothelial cell area (Avg) (μm<sup>2</sup>) changed from a mean value of 377.41±31.38preoperatively to a mean value of 373.77±36.51at 1-2

| Item                              | Best corrected visual acuity (Preoperative) | Uncorrected visual acuity (Post-operative) | t-test | P-value | Significance    |
|-----------------------------------|---|--|--------|---------|-----------------|
| Mean value and standard deviation | 0.55±0.22                                   | 0.61±0.17                                  | 1.06   | >0.05   | Non-significant |

**Table 3:** Comparison of the mean value and standard deviation of the preoperative best corrected visual acuity and the postoperative uncorrected visual and their comparison by t-test among patients under study.



**Chart 1:** The mean value for the visual acuity in Snellen lines both preoperatively (BCVA) and postoperatively (UCVA) among patients under study.

| Item  | Preoperative mean value and standard deviation | Post-operative mean value and standard deviation | t-test | P-value | Significance       |
|---|--|--|--------|---------|--------------------|
| Cell density(CD)/ mm <sup>2</sup>                           | 2667.05±218.35                                 | 2697.32±245.97                                   | 1.07   | >0.05   | Non-significant    |
| Average cell area(Avg)                                      | 377.41±31.38                                   | 373.77±36.51                                     | 0.88   | >0.05   | Non-significant    |
| Coefficient of variation in cell size(CV)<br>=Polymegathism | 28.22±6.98                                     | 26.09±4.39                                       | 1.56   | >0.05   | Non-significant    |
| Hexagonal cells percentage(Hex%)<br>=Pleomorphism           | 68.18±8.35                                     | 69.95±6.47                                       | 0.97   | >0.05   | Non-significant    |
| Corneal thickness (CT) μ                                    | 539.36±17.05                                   | 393.68±29.97                                     | 13     | <0.01   | Highly-significant |

**Table 4:** The mean values and standard deviations for various studied corneal endothelial cell changes both and after PRK with mitomycin among patients under study.

months postoperatively with t-test value of 0.88 denoting a non-significant difference ( $p>0.05$ ) (table 4 and chart 3). The average coefficient of variation in cell

size(CV) i.e; polymegathism changed from a mean value of  $28.22\pm 6.98$  preoperatively to a mean value of  $26.09\pm 4.39$  at 1-2 months postoperatively with t-test

**Correspondence to:**

Dr. Tamer AR

<sup>1</sup>Refractive Unit, Ophthalmology Department, Research Institute of Ophthalmology

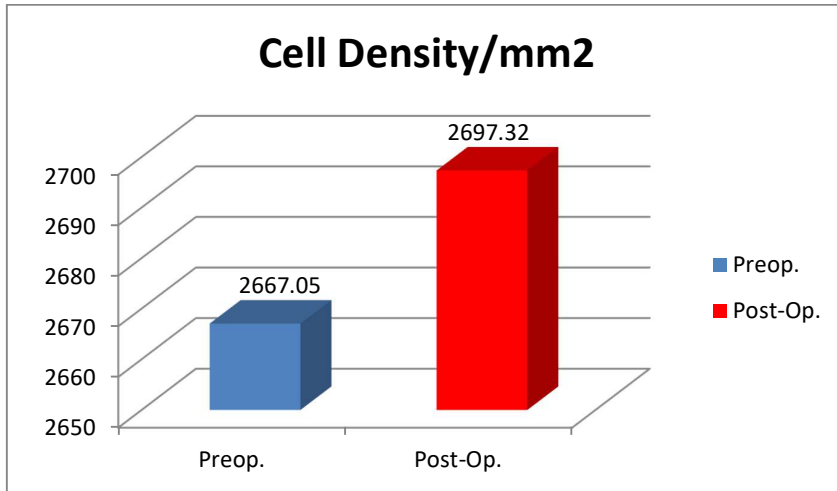
©JORS

Email: [tamerrefai@hotmail.com](mailto:tamerrefai@hotmail.com)

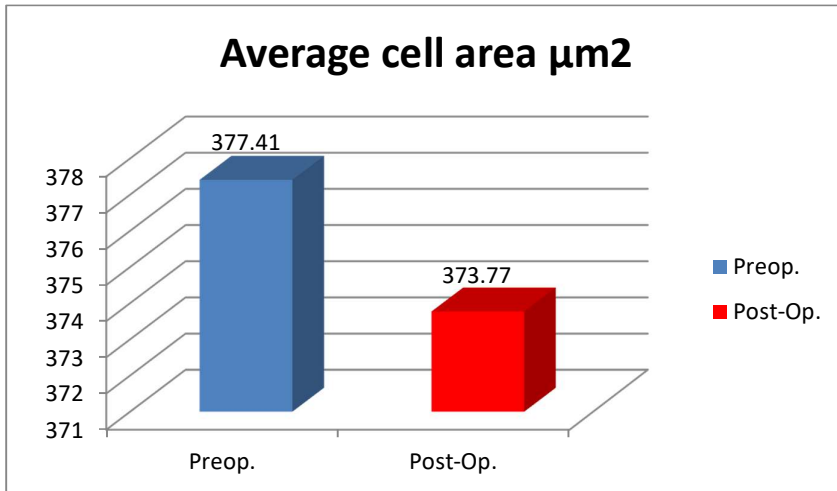
<http://jors.journals.ekb.eg/>

Full list of author information is available at the end of the article.

value of 1.56 denoting a non-significant difference ( $p>0.05$ ) (table 4 and chart 4).



**Chart 2:** Mean value for the corneal cell density/mm<sup>2</sup> both preoperatively and postoperatively among patients under study



**Chart 3:** Mean value for the average corneal endothelial cell (μm<sup>2</sup>) area both preoperatively and postoperatively among patients under study

The average hexagonal cells percentage (Hex%) i.e; pleomorphism, changed from a mean value of 68.18±8.35 preoperatively to a mean value of 69.95±6.47 at 1-2 months postoperatively with t-test value of 0.97 denoting a non-significant difference ( $p>0.05$ )(table 3 and chart 5).

The corneal thickness(μ) by specular microscopy, changed from a mean value of 539.36±17.05

preoperatively to a mean value of 393.68±29.97 at 1-2 months post-PRK with mitomycin, with t-test value of 3.0 indicating a highly significant difference ( $p<0.01$ ) (table 3 and chart 6).

Pearson correlation test revealed a non-significant correlation( $P>0.05$ ) between length of mitomycin C exposure and post-PRK changes in the cell density(CD) ( $r=0.14$ ),average cell area change ( $r=-0.18$ ) as well as

**Correspondence to:**

Dr. Tamer AR

<sup>1</sup>Refractive Unit, Ophthalmology Department, Research Institute of Ophthalmology

Email:[tamerrefai@hotmail.com](mailto:tamerrefai@hotmail.com)

Full list of author information is available at the end of the article.

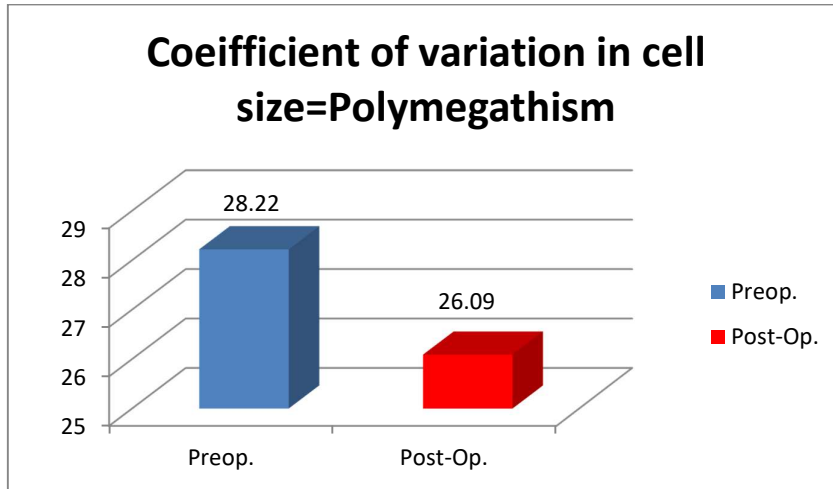
©JORS

<http://jors.journals.ekb.eg/>

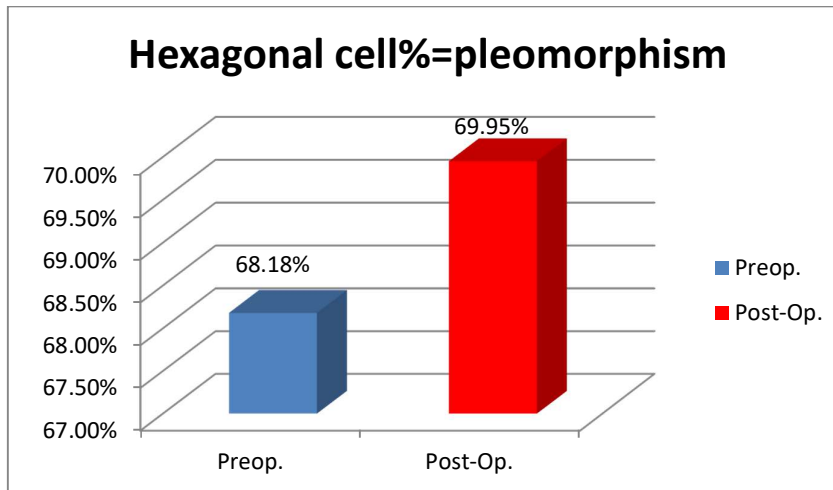


coefficient of variation in cell size (CV) ( $=0.02$ ) but there was a statistically significant correlation ( $p<0.05$ ) between the length of mitomycin C exposure and post-

PRK changes in the hexagonal cells percentage ( $r=0.37$ ) (**table 5**).



**Chart 4:** Mean value for the average coefficient of variation in cell size (polymegathism), both preoperatively and postoperatively among patients under study.



**Chart 5:** Mean value for the average hexagonal cell percentage (pleomorphism), both preoperatively and postoperatively among patients under study.

## Discussion

Mitomycin C had been commonly following photorefractive keratectomy to prevent postoperative haze formation by modifying wound healing response through inhibiting corneal fibroblast cell proliferation<sup>19-20</sup>. However, some studies showed significant endothelial cell changes after PRK with mitomycin<sup>15-16</sup>.

Gharaee *et al* 2018, studied 48 cases that were treated with PRK with mitomycin application, with a mean age of  $26.70 \pm 4.89$  years (range, 18–34 years). Postoperative cell density, cell size and polymegathism did not significantly change and these results agreed with our study. On the other hand, Gharaee *et al*, found that pleomorphism ( $P = 0.003$ ) and coefficient of variation (CV) ( $P = 0.016$ ) were significantly increased.

## Correspondence to:

Dr. Tamer AR

<sup>1</sup>Refractive Unit, Ophthalmology Department, Research Institute of Ophthalmology

Email: [tamerrefai@hotmail.com](mailto:tamerrefai@hotmail.com)

Full list of author information is available at the end of the article.

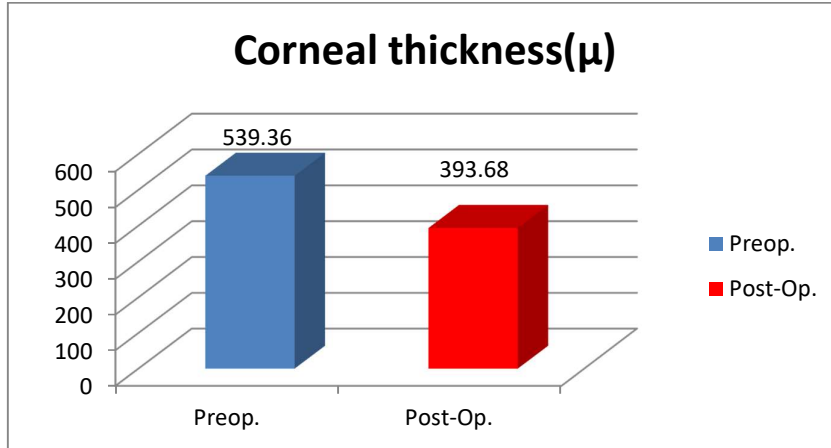
©JORS

<http://jors.journals.ekb.eg/>

None of these parameters was related to the length of MMC application<sup>15</sup>.

Neamah et al 2017, studied 22 cases, in which PRK with mitomycin application for 50 seconds were applied for a relatively older age (range 18-40 years, mean 27.5±6.16 years) compared to our study (range 18-39

years, mean 26.26±6.68), they found that the endothelial cell density was reduced from 5.4-6.8% 3 months after PRK with mitomycin<sup>16</sup> and this finding was not found in our study which was performed on a relatively younger age. But they found that there was no significant change in the coefficient of variation in cell size (CV) and this agreed with our study.



**Chart 6:** The mean value for the average central corneal thickness (μ) by specular microscopy, both preoperatively and postoperatively among patients under study.

| Correlation between mitomycin C exposure time <i>versus</i> studied endothelial change | Pearson correlation "r" | P-value | Significance              |
|--|-------------------------|---------|---------------------------|
| <b>Cell density(CD)/ mm<sup>2</sup> change</b>   | 0.14                    | >0.05   | Non-significant           |
| <b>Average cell area(Avg) change</b>   | -0.18                   | >0.05   | Non-significant           |
| <b>Coefficient of variation in cell size(CV) =Polymegathism change</b>                 | 0.02                    | >0.05   | Non-significant           |
| <b>Hexagonal cells percentage(Hex%) =Pleomorphism change</b>                           | 0.37                    | <0.05   | Statistically significant |

**Table 5:** Pearson correlation between the length of time of mitomycin C exposure and the post PRK-mitomycin endothelial cell changes among cases under study.

Zare et al 2011, studied 42 eyes with mean age of 26.2±6.3, in which mitomycin was applied for only 40 seconds after PRK, and they found no significant change in endothelial cell density(CD), mean cell area (MCA) or coefficient of variation in cell size(CV) and this agreed with the results of our study, in which we applied a much longer mitomycin exposure time<sup>17</sup>.

In our study, the age ranged from 18-39 years (mean 28.10±6.24). The corrected sphere (D) ranged from -3.0 to -10.0 (mean -6.82 ± 2.08), cylinder (D) ranged from -1.0 up to -4.5 (mean value of -2.56 ± 1.13) and the total sphero-cylindrical correction (D) ranged from -6.25 to -11.25 (mean -8.78 ± 1.52). No significant corneal haze

developed in any of the cases included in the study. The corneal endothelial cell density(CD)/ mm<sup>2</sup>, the average endothelial cell area (Avg) (μm<sup>2</sup>), the average coefficient of variation in cell size (CV) i.e; polymegathism and the average hexagonal cells percentage(Hex%) i.e; pleomorphism did not show any significant postoperative change. These results which agreed with those found with Zare et al 2011, but were much better than those found with Gharaee et al 2018, and Neamah et al 2017; in spite of using higher concentration and a much longer application time which could be related to excessively copious irrigation of the corneal bed, conjunctival sac and puncti with about 30ml of BSS after mitomycin application. A non-

**Correspondence to:**

Dr. Tamer AR

<sup>1</sup>Refractive Unit, Ophthalmology Department, Research Institute of Ophthalmology

Email: [tamerrefai@hotmail.com](mailto:tamerrefai@hotmail.com)

Full list of author information is available at the end of the article.

©JORS

<http://jors.journals.ekb.eg/>



significant correlation ( $P>0.05$ ) existed between length of mitomycin C exposure and post-PRK changes in the cell density (CD) ( $r = 0.14$ ), average cell area change ( $r=-0.18$ ) as well as coefficient of variation in cell size (CV) ( $=0.02$ ) but there was a statistically significant correlation ( $p<0.05$ ) between the length of mitomycin C exposure and post-PRK changes in the hexagonal cells percentage ( $r = 0.37$ ). These results agreed with those found by Gharaee et al 2018.

### Conclusion

Photorefractive keratectomy using higher concentration of mitomycin C (0.027%) for exposure time of (2.20 - 3 minutes) provided excellent refractive and visual results for high myopia and astigmatism without significant negative effects on the corneal endothelium.

### Acknowledgments

Acknowledgements are made for the Cornea and Refractive Unit of the Research Institute of Ophthalmology, Giza, Egypt that funded this research.

### Financial disclosure

There was no commercial or proprietary interest in any of the materials discussed in this article.

### Conflict of Interest

No conflict of interest to be declared.

### Author details

Dr. Tamer Adel Refai, MD<sup>1</sup>, Dr. Olfat A. Hassanin, MD<sup>1</sup>

1. Refractive Unit, Ophthalmology Department, Research Institute of Ophthalmology

Received Date: November 26, 2018  
Accepted Date: May 9, 2020  
Published Online: September 12, 2020

### Reference

1. Yuen LH, Chan WK, Koh J, Mehta JS, Tan DT; Sing Lasik Research Group. A 10-year prospective audit of LASIK outcomes for myopia in 37,932 eyes at a single institution in Asia. *Sing Lasik Research Group. Ophthalmology* 2010;117(6):1236-44.
2. Dawson DG, Randleman JB, Grossniklaus HE, O'Brien TP, Dubovy SR, Schmack I. Corneal ectasia after excimer laser keratorefractive surgery: histopathology, ultrastructure, and pathophysiology. *Ophthalmology* 2008; 115(12):2181-91.
3. Holladay JT, Dudeja DR, Chang J. Functional vision and corneal changes after laser in situ keratomileusis determined by contrast sensitivity, glare testing, and corneal topography. *J Cataract Refract Surg* 1999;25: 663-669.
4. Hatch BB, Moshirfar M, Ollerton AJ, Sikder S, Mifflin MD. A prospective, contralateral comparison of photorefractive keratectomy (PRK) versus thinflap LASIK: assessment of visual function. *Clin Ophthalmol* 2011;5:451-457.
5. Netto MV, Mohan RR, Sinha S, Sharma A, Gupta PC, Wilson SE. Effect of prophylactic and therapeutic mitomycin C on corneal apoptosis, cellular proliferation, haze, and long-term keratocyte density in rabbits. *J Refract Surg* 2006; 22:562-574.
6. Wallau AD, Campos M. One-year outcomes of a bilateral randomized prospective clinical trial comparing PRK with mitomycin C and LASIK. *Br J Ophthalmol* 2009; 93:1634-1638.
7. Talamo JH, Gollamudi S, Green WR, De La Cruz Z, Filatov V, Stark WJ. Modulation of corneal wound healing after excimer laser keratomileusis using topical mitomycin C and steroids. *Arch Ophthalmol* 1991;109:1141-1146.
8. Pietila J, Makinen P, Pajari T, Suominen S, Keskinisula J, Sipila K, et al. Eight-year follow-up of photorefractive keratectomy for myopia. *J Refract Surg* 2004; 20 (2):110-115.
9. Llovet F, de Rojas V, Interlandi E, Martin C, Cobosoriano R, Ortega-Usobiaga J, et al. Infectious keratitis in 204 586 LASIK procedures. *Ophthalmology* 2010;117 (2):232-238 e231-234.
10. Zhao LQ, Wei RL, Ma XY, Zhu H. Effect of intraoperative mitomycin-C on healthy corneal endothelium after laser-assisted subepithelial keratectomy. *J Cataract Refract Surg* 2008;34 (10):1715-1719.
11. Stojanovic A, Nitter TA. Correlation between ultraviolet radiation level and the incidence of late-onset corneal haze after photorefractive keratectomy. *J Cataract Refract Surg* 2001; 27 (3):404-410.
12. Diakonis VF, Pallikaris A, Kymionis GD, Markomanolakis MM. Alterations in endothelial cell density after photorefractive keratectomy with adjuvant mitomycin. *Am J Ophthalmol* 2007;144(1): 99-103.
13. Shalaby A, Kaye GB, and Gimbel HV. Mitomycin C in photorefractive keratectomy. *Journal of Refractive Surgery* 2009;25(1):93-97.

### Correspondence to:

Dr. Tamer AR

<sup>1</sup>Refractive Unit, Ophthalmology Department, Research Institute of Ophthalmology

©JORS

Email: [tamerrefai@hotmail.com](mailto:tamerrefai@hotmail.com)

<http://jors.journals.ekb.eg/>

Full list of author information is available at the end of the article.

14. Lee DH, Chung HS, Jeon YC, Boo SD, Yoon YD, Kim JG. Photorefractive keratectomy with intraoperative mitomycin-C application. *Journal of Cataract and Refractive Surgery* 2005;31(12):2293-2298.
15. Gharaee H, Zarei-Ghanavati S, Alizadeh R, Abrishami M. Endothelial cell changes after photorefractive keratectomy with graded usage of mitomycin C. *IntOphthalmol* 2018; 38:1211–1217.
16. Neamah GT, Al Amedee H, Al SamakAM , Kareem AA. The effect of mitomycin C on corneal endothelial cell count after photorefractive keratectomy. *Journal of Natural Sciences Research* 2017;24(7):73-77.
17. Zare M, Jafarinasab MR, Feizi S, Zamani M. The effect of mitomycin-C on corneal endothelial cells after photorefractive keratectomy. *Journal of ophthalmic & vision research* 2011; 6 (1):8-12.
18. Kim JM, Kim JC, Park WC, Seo J-S, Chang HR. Effect of Thermal Preconditioning Before Excimer Laser Photoablation. *J Korean Med Sci* 2004 Jun; 19(3): 437–446.
19. Gambato C, Ghirlando A, Moretto E, Busato F, Midea E . Mitomycin C modulation of corneal wound healing after photorefractive keratectomy in highly myopic eyes. *Ophthalmology* 2005; 112 (2):208-218.
20. Majmudar PA, Forstot SL, Dennis RF, Nirankari VS, Damiano RE, Brenner R et al. Topical mitomycin-C for subepithelial fibrosis after refractive corneal surgery. *Ophthalmology* 2000;107 (1):89-94.

**Correspondence to:**

Dr. Tamer AR

<sup>1</sup>Refractive Unit, Ophthalmology Department, Research Institute of Ophthalmology

Email: [tamerrefai@hotmail.com](mailto:tamerrefai@hotmail.com)

*Full list of author information is available at the end of the article.*

©JORS

<http://jors.journals.ekb.eg/>